

APPENDIX B

ADDITIONAL HISTOLOGY IMAGES

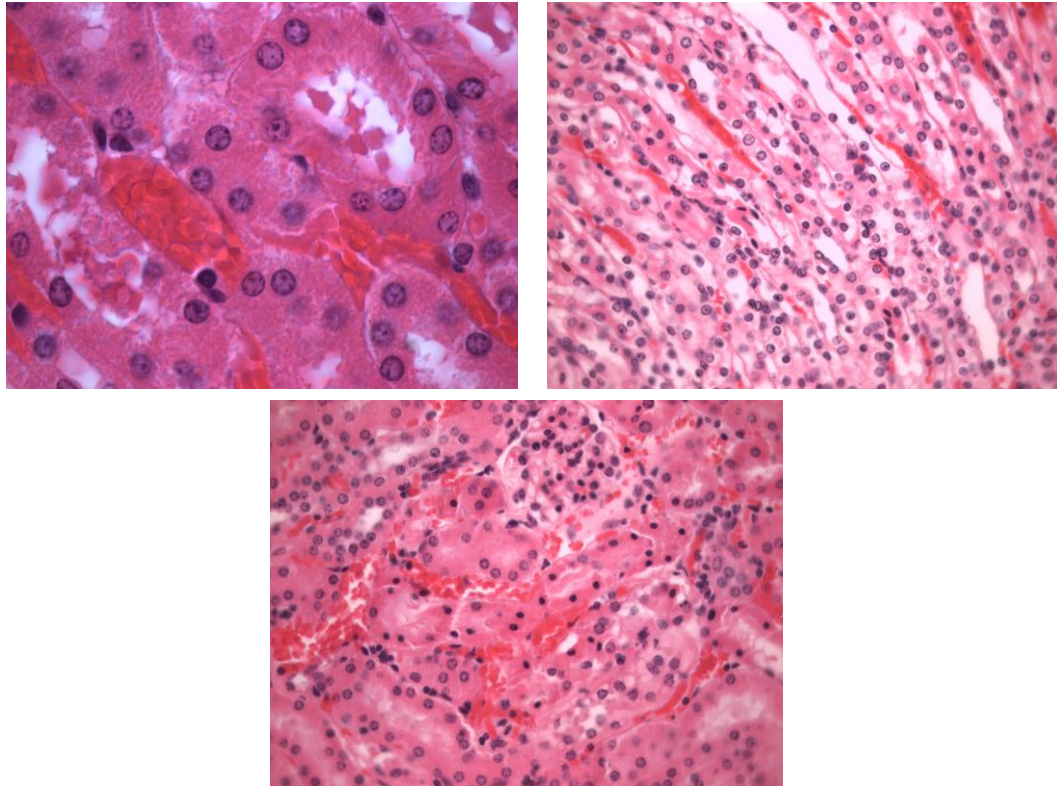


Figure 55. Three panels from the 20 μ M sections showing slight swelling and protein casts within the cells.

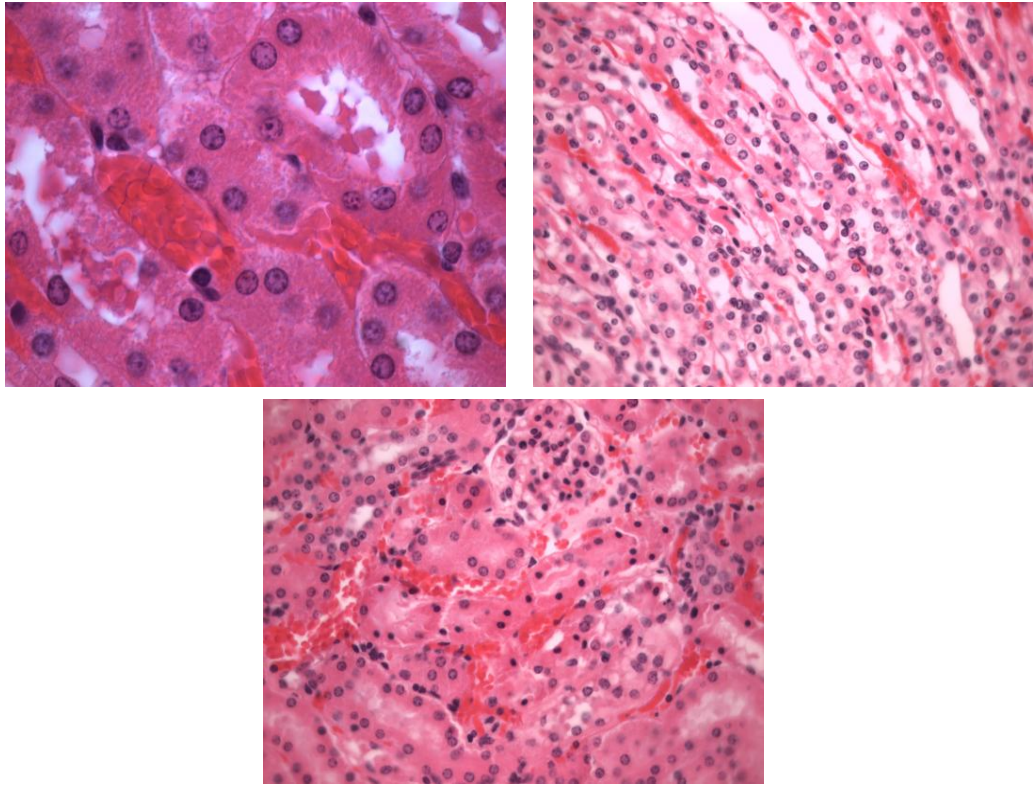


Figure 56. Histology sections taken from the 40 μ M injection group. These slides show increased necrosis in the tubules and epithelial swelling. All photos are 40x magnification.